



अ० भा० आ० सं० अस्पताल / A.I.I.M.S. HOSPITAL  
 बहिरंग रोगी विभाग / Out Patient Department

अस्पताल में जन्तु शिकार तथा शिश्न / SMOKING IS PROHIBITED IN HOSPITAL PREMISES

OR-74442

MANIS P.O.B

5/2/24



रोगी पहचान चिह्न  
 UHID: 107830583



रोगी नाम: ANJAN RAJ

कक्षा / Room: C-217

कक्षा नं.: N4

यूनिट: PSCC PAFES

OPR-6

बहिरंग रोगी सं./O.P.D. Regn. No.

उम्र / Age

पता / Address

107830583

डॉ. नरेन्द्रा कर्मा  
 स्टाफ़ / Staff  
 00349: JAMUNPUR KHASERA BHAR  
 पिन कोडा  
 पिन 757037(24)  
 रोगी प्रकार



Reporting: 22/02/24  
 0578 2024

रोगी / Diagnosis

Suspected Neuroblastoma

दिनांक / Date

4/1

उपचार / Treatment

MANAN SEWANGI

10/11/24  
 115g  
 115g  
 7/10/24  
 4/10/24  
 25/10/24 → to be  
 prescribed

PT/WR (2)

5700 (150x10<sup>9</sup>)  
 2570

7400 (11x10<sup>9</sup>)  
 3620

ADW  
 एन क्रॉस (5/12/24) एनल रस  
 5/10/24

Uc - 14/0.1

UR - 33

CRP - 91/39

ESR - 52/51

ALP - 787

Cesilim - 5078

Vit-B - 1350



CLEAN AND GREEN AIIMS / एक का पत्ती लहना, अंधाधुंध में काट नका  
 अंगदान जीवन का बहुमूल्य उपहार / ORGAN DONATION - A GIFT OF LIFE  
 O.R.B.O. AIIMS: 24585360, 26593444. www.orbo.org Helpline - 1060 (24 hrs service)

आर्य अस्पताल  
 All India Institute of Medical Sciences  
 New Hospital  
 Manasgatal nhy.gov.in



अशिल भारतीय आरुविक्षान संस्थान, नरुं दिल्ली  
 ALL INDIA INSTITUTE OF MEDICAL SCIENCES, NEW DELHI  
 DEPARTMENT OF PATHOLOGY

Patient Name	ADYAN RAI	ETHNOS	IN7830581
Accession No	S2447685	ETH Name	NEOPLASIA
Age Sex	5Y /M/L	Additional ID	KS15460
Phys Dept	Pediatrics	Unit	NA
Consultant Incharge	Dr. Rakina Sethi	Request Date/Time	18-10-2024 10:31:14
		Receiving Date/Time	18-10-2024 12:00:33

**HISTOPATHOLOGY REPORT**

**GROSS EXAMINATION:**

Accession No. S2447685A

Specimen labelled as "left supraorbital mass biopsy" comprises of four linear cell cores measuring 0.7x0.5x0.1, 0.4x0.3x0.1 cm

**MICROSCOPIC EXAMINATION:**

Sections examined is poorly preserved, however shows evidence of necrosis and a malignant small round cell tumor with neuronal chromatin characteristics. tumor cells are positive for P-100/78 while negative for LCA, desmin and synaptophysin. Mitotic-karyorrhexis index (MKI) is intermediate (2-3).

Diagnosis: Neuroblastoma, poorly differentiated.

Fluorescence in situ hybridization for MYCN is being performed and a supplementary report will follow.

**DIAGNOSIS:**

S2447685A

Left supraorbital mass biopsy

• Poorly differentiated neuroblastoma, pediatric (9500)3

End Report

Reporting Resident: Dr. Vijayashruti

Reporting Faculty: Dr. Lavleen Singh

Reporting Date/Time: 18-10-2024 20:52

**Disclaimer:**

- This report is electronically generated and does not require a signature or stamp to be considered valid.
- This computer diagnosis is to be interpreted by the treating physician in conjunction with clinical features, imaging, and other investigations.

To

RPC Casualty

Kindly examine child

clo ~~has~~ Metastatic neuroblastoma  
NE

= ? epinephrine

~~Dr. Rama~~  
~~Dr. Pedoma~~  
MANAV SEWANGO

PM CARE

on examination

HR: 160/min

RR: 34

T: 96°F

Wegm side  
no fever

PT: 17/14

→ RS: NE = BS clear

CVS: S1S2 heard

IA: soft NT  
L2S2

SpO2 99%

CNS: 4CS 15/15

fallon (+)

Ad 4

18/10/26 → Hb: 7.8

- TO refer to Pediatric Emergency

WBC: 6420

→ send urgent CBC

HMC: 4060

→ do CXRAY

PC: 83000

→ PRBC transfusion  
→ Ped on 10 AM to review

Dr. Rama

Dr. Pedoma

# Diagnostic Work UP & Risk Stratification

Clo • Metastatic neuroblastoma

USG outside: (1) suprarenal mass w/ tiny calcification.

4.5 x 4 cm, multiple enlarged retroperitoneal  
mesenteric lymph nodes.

CT Abdomen: RC discussion.

- large (1) suprarenal mass with multiple tiny calcifications extending inferiorly, encasing renal artery.
- multiple enlarged mesenteric lymph nodes
- mass causing mild hydronephrosis
- retroperitoneal extension till paravertebral region
- inferiorly till bifurcation of common iliac artery.
- pericardial deposit BL
- enlarged thymus, spleen, pancreas.

PET: Multiple SUV bone lesion.

- (+) frontal bone (+)
- (+) temporal bone (+)
- dural thickening of frontal occipital
- BL periorbital deposit
- BL cervical, axillary, mediastinal, retroperitoneal lymphatic
- (1) suprarenal mass

Name of treatment protocol Metastatic Neuroblastoma.

# Consultations

Plan

1) Kishan loan  $2^2 - 2^2 - 2^2 - 2^2 - 2$

4 terms

2) optimum option for

(A) Discharge  
locality

} for security

3) To start theme (KAPU 1000)

4) At A state in on day 2

Common to capital & technology

5) To give 40% share (100 - 1000)

6) 20% share

7) To full share on day 1

8) To full share on day 2 (1000) for 10 days

To complete  
100% 100%

100% 100%  
100% 100%  
100% 100%

MANAV SEWA NGO

IT demands

→ collect data / ml data input

IV PEXA 2000  
IV Project long term

cycle 1

2000

→ 10 simulation 2000 about plan  
10 CARBORAN 2000 for front work  
10 2000 2000 for the 1000  
10 2000 2000 for the 1000  
10 2000 2000 for the 1000

To complete  
100% 100%

100% 100% from day 1 day 2 till day 7 (unit cost change)

to take population into

4  
R. Rama  
St. Paul's

To,  
The Bankers

Dear Sirs,

Kindly advise me about the:

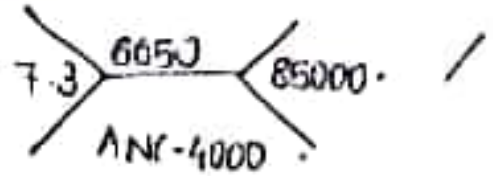
- ① my character [3000000] - ① unit
- ② my income [1000000] - ① unit
- ③ my current income [500000] - ① unit
- ④ my net worth [1000000] - ① unit
- ⑤ my credit [1000000] - ① unit
- ⑥ my assets [3000000] - ① unit

Yours faithfully,

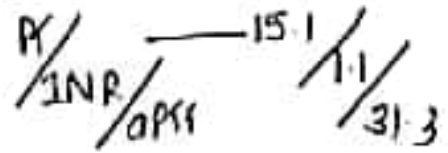
Adviso Dr. Prof. Rachna Seli Meary

08/09/24

3. Exp. Paracetamol (25mg/5ml) 5ml PO SOS



2. Exp. Ibuprofen plus 2.5ml PO twice daily



3. Palliative medicine consultation (Room no. 60 / IRCH)

U/A - 16% U and - 3.3

4. NGP insertion - MCH Dayan

CO/P - 9.1/3.9 Na/K - 13.4/4

NGP feed 60ml Q2H 3x daily

18/PB - 0.3/0.1 NGI/ALP - 52/31/0.8

followed by 80ml Q2H

Varikn - 5098

- pain
- NG feed
- CT scan
- CD/E

5. CD diagnosis confirmed

Expedite biopsy

31M / 6y

7/10/24

RECEIVED

DATE 01/10/24

TIME

BY (Signature)

MANAN SEWANGO

6. CDCEchemo.

7. Date for BMA/Biopsy. 2/10/24

8. NYV -> 03/07/24 PLSC @ 2pm

20 feeds -> 14.5g DT RUMORS





श्री श्री श्री श्री अण्डमान / A.I.M.S. HOSPITAL

एन सी ई सी एन  
एन सी ई सी एन  
एन सी ई सी एन  
एन सी ई सी एन  
एन सी ई सी एन

WWW: [www.aims.gov.in](http://www.aims.gov.in)  
C-210  
F35  
A-1, P.O.

Outpatient Department  
PROHIBITED IN HOSPITAL PREMISES

OPD-6

DR. HARENDRA KUMAR  
BY DR. T. D. SINGH  
DR. HARENDRA KUMAR  
DR. T. D. SINGH  
DR. HARENDRA KUMAR  
DR. T. D. SINGH



A. No. / अण्डमान नं. / OPD Regn No.

Sex /  
Age

DOB / Address

Diagnosis /  
Disease

Date /  
Visit

Treatment /  
Visit



18/10

→ received 10/10/20

→ 1/1/20

Network copy

1/1/20

9/10

1/1/20

1/1/20

MANAV SEVA ANGO



CLEAN AND GREEN AIMS /  
ORGAN DONATION - A GIFT OF LIFE  
O R B O, AIMS, 2658030, 2658344 www.aims.org Helpline - 1050 (24 hrs service)





Dietchant → Given

19/09/24  
No % fever / vomiting / bleeding  
manifestations

% — Affected.  
Pallor (+) .  
Chest clear, NVP

Prophylaxis  
(R) >> U .  
Unresolved  
Congestion .

Received PRBC yesterday  
Post PRBC  
18/09/24.  
6400  
78 ——— 83000  
ANC-4060

Adt  
1. HIV, + ——— Galera: 1

Comm. 5 / AD ICIC

2. HR Ag, anti HIV .

3. Date for chemo ——— 11 days later

4. PRC regularization ——— 2/10/24

5. Continue N4 feeding .

6.  $\frac{N}{V}$  ——— 2/10/24 \* POC @ 2pm

- ✓ PET
- ✓ Prophy  
↳ JHrawada a
- ✓ Viral markers:  
Mantoux test
- ✓ aDecho

DR  
Dr. [Signature]  
Jt Resident  
Cell Resident  
Paediatric Oncology  
AIIMS, New Delhi



आर्य समाज अस्पताल / A.I.I.M.S. HOSPITAL  
बाह्य रोगी विभाग / Out Patient Department

आर्य समाज अस्पताल, एन.ए. रोड, इंदौर, मध्य प्रदेश / All India Institute of Medical Sciences Hospital, New Delhi



Reg. No. 117830003  
 Date of Birth: 20/05/2003  
 Name: DR. HARSHAN KUMAR  
 Address: ...  
 Age: ...  
 Date: ...  
 Barcode: ...  
 Stamp: ...  
 Handwritten: Pediatric 10/10/2024

Post Diagnosis: (Supra)renal mass & evaluation. (?Metastatic neuroblastoma)

<p>11 Kg</p> <p>BP →</p> <p>11 Kg</p>	<p>Examination:</p> <ul style="list-style-type: none"> <li>Examination of abdomen: ...</li> <li>Examination of chest: ...</li> <li>Examination of spine: ...</li> <li>Examination of lymph nodes: ...</li> </ul>	<p>Investigations:</p> <ul style="list-style-type: none"> <li>USG abdomen: ...</li> <li>CT abdomen: ...</li> <li>MRI spine: ...</li> <li>MIBC: ...</li> <li>Mast biopsy: ...</li> </ul>	<p>Diagnosis:</p> <ul style="list-style-type: none"> <li>Metastatic neuroblastoma</li> <li>Multiple enlarged retroperitoneal lymph nodes</li> <li>Multiple enlarged retroperitoneal lymph nodes</li> <li>Multiple enlarged retroperitoneal lymph nodes</li> <li>Multiple enlarged retroperitoneal lymph nodes</li> </ul>
---------------------------------------	--	---	--

CNI  
EchoLab

4:30pm

62

MR. 4

अखिल भारतीय आयुर्विज्ञान संस्थान, नई दिल्ली- 110029  
All India Institute of Medical Sciences, New Delhi-110029

परामर्श अभिलेख / CONSULTATION RECORD

नाम Name	आयु Age	लिंग Sex	विवाहिक स्थिति Marital Status	यू एन आर सी नं. I.M.D. No.
सेवा Service	कमरे नं. Ward	बिस्तर Bed	व्यवसाय Occupation	अपेक्षा Request
Retained by Dr. SR/Padma Gooly Requesting Doctor			to Dr. SR/Padma Gooly Consultant & Specialty	

Findings :

Date :

(Dr. Subramanian)

Dear colleagues,

kindly consider echo for our patient — k/c

metastatic neuroblastoma planned for antineoplastic based.

Diagnosis or Impression :

chond. — See the needful.

Thanking You.

Recommendations:

*[Signature]*

*[Signature]*  
 DR. ANA SHUKLA PR  
 DM Resident  
 Pediatric Oncology  
 AIIMS, New Delhi

CC/PO man (62)  
 Dr. Subramanian  
*[Signature]*

Consultant



दक्षिण बिहार ग्रामीण बैंक  
**Jeevika Bihar Gramin Bank**

Head Office: Shri Vishnu Commercial Complex  
NH-30, New Bypass, Near BP Highway Services Petrol Pump,  
Asochak, Patna-800030  
Phone - 0612-2385114

**L & A Department**

Ref: L/CREDIT/JEEVIKA/204

Date: 24.10.2024

The Senior Regional Manager (AGM)/ Regional Manager  
All Regional Offices

**SUB: DISBURSEMENT IN SHG A/C ON 29 & 30 Oct 24**

Kindly go through the L & A circular letter no. 08/24 dt 21.05.24, and 09/24 dt 29.07.24 in which instructions have been given regarding individual finance to Jeevika members, linkages and disbursement of SHG. It is decided to boost disbursement in eligible existing accounts.

- Keeping in view of Festive season, Disbursement is planned on 29 & 30 Oct 2024.
- List of accounts having good repayment history is provided in excel sheet.

The detailed action points are as under.

Event	Date
Disbursement:	29 - 30 Oct 2024

Please note that the growth in SHG advances during this month is very low, so the above instructions must be complied meticulously and percolate the necessary instructions to your team at Branches and Regional Office to meet the Jeevika members personally for desired result.

  
General Manager



277



# अ० भो० आ० सं० अस्पताल / A.I.I.M.S. HOSPITAL Out Patient Department

सि. प्र. वि. सं. १०८३  
आ. सं. १०८३  
आ. सं. १०८३  
आ. सं. १०८३  
आ. सं. १०८३

रोग / Disease  
C-311  
कक्षा / Ward  
F18  
उप-वि. फार्मासी

किंग्स प्रोटेक्टोड इन हॉस्पिटल प्रिन्सिपल

OPR-6

ना. प्र. वि. सं. / DPD Regn. No.

सि. प्र. वि. सं. १०८३  
आ. सं. १०८३  
आ. सं. १०८३  
आ. सं. १०८३  
आ. सं. १०८३



लिंग / Sex	वय / Age	पता / Address

रोग / Diagnosis

Suspected Metastatic Neuroblastoma.

रोग / Date

38

10/9/24

ECHO - @ study.

PET - Lt. suprarenal mass

Metast to multiple LN, ext. skeletal, B/L Paravertebral (D<sub>1</sub>-D<sub>10</sub>)  
Nodular pleural thickening, subpleural nodules & paravertebral nodules  
B/L lung.

Adv

NG intubation -> Day Care & to counsel for diet

PRP + transfusion -> 18/10/24 Bam Day Care

Main Blood Bank

Oncopath disc

Blood Bank -> kindly bleed donor for this patient

F/U 19/10/24 ~ CBC

Syn POM (75mg/5ml) 6ml po TDS



CLEAN AND GREEN AIIMS / एक ही छत, एक ही मकान, एक ही सेवा  
अंगदान - अंग दान / ORGAN DONATION - A GIFT OF LIFE  
DR B. O. AIIMS, 2658261, 2658244, www.aiims.org helpline - 1188 (24 hrs service)





NEW DELHI UNIVERSITY, New Delhi  
**ALL INDIA INSTITUTE OF MEDICAL SCIENCES, NEW DELHI**  
**DEPARTMENT OF PATHOLOGY**

Case No.	1811241	Slide No.	1811241
Examination No.	1811241	Field No.	1811241
Ref. No.	1811241	Additional ID	N/A
Ref. Dept.	Pathology	Site	N/A
Ref. Physician	Dr. Lakshmi Singh	Report Date/Time	11-10-2024 09:30:05
		Reporting Date/Time	11-10-2024 11:37:47

**HISTOPATHOLOGY REPORT**

**GROSS EXAMINATION:**

Examination No. 1811241

Specimen submitted as: Right hemi-mastectomy biopsy - compression of single frozen NBE core measuring 1.5 cm in length.

Examination No. 1811242

Specimen submitted as: Left hemi-mastectomy biopsy - compression of three frozen soft cores measuring 0.8 cm and 0.8 cm in length.

**MICROSCOPIC EXAMINATION:**

1. HE: Sections examined in H&E stain and show metastatic spread of malignant small round cell tumor with crush artifact. The tumor occupies 80% of interlobular spaces. The tumor cells are immunopositive for PTH43.

Note: The patient has a previous histopathology examination number 1811241 which has been reviewed and shows poorly differentiated neuroblastoma.

**DIAGNOSIS:**

1811241	Right hemi-mastectomy biopsy	Right	Metastatic neuroblastoma
1811242	Left hemi-mastectomy biopsy	Left	Metastatic neuroblastoma

Reporting Physician: Dr. Vijayashankar

Reporting Faculty: Dr. Lakshmi Singh

Reporting Date/Time: 28-10-2024 14:2

**Disclaimer:**

- The report is based on the information provided and does not represent a guarantee of accuracy or quality of the specimen received.
- The laboratory is not responsible for the handling, collection, or transportation of specimens, including any delay or misdirection.

Department of Pediatrics  
Division of Pediatric Oncology  
All India Institute of Medical Sciences, New Delhi

CK-94942



शरीरमाद्यं खलु धर्मसाधनम्

Patient Note Book

Name : ..... ARYAN RAJ .....

UHID : ..... 102820583 .....

Diagnosis: ..... C10 Metastatic Neuroblastoma .....

MANAV SEWA NGO

22/10/24

@ Vaycece

~ received (2) of 0300 ~

CINU

prophylaxis - gun z Emset  
dexamethasone  
oral olanzapine

Advice

① 70 gu sy. 60st 55 ug 50 once daily

23/10	22/10
24/10	23/10
25/10	24/10
26/10	25/10
27/10	26/10

MANAV SEWANGO

② next opp visit on 2/11/2024

7 CBC

Sat 5AM

10 ml 2w 5.9  
2sp

③ syp septan [40mg/ml]

④ syp citrizing [5mg/ml] 2.5 ml hs x 7

MINOR PIERCED...  
DATE: 22/10/24



- Multiple pleomorphic, purpura, pale area, abnormal
- inguinal lymph node seen few of them shows tiny cat
- partial necrosis, large on increasing - 2cm - (300) imperi
- pancreatic nodes

- Multiple small nodular lesions seen on the spleen

CT scan - - ① kidneys - large left Suprahilar mass & multiple  
rim calcification.

12/19  
Bx exam - done, ~~sent~~ ~~reports~~ ~~to~~ ~~RA~~.  
inpiration - ~~abnormal~~ narrow stenosis between  
bronchi

The child was referred for further workup to RA.

On examination: Vitals (T: 101.2) | R: 22 | P: 100 | SpO2: 96  
 P + I - U - W - C -  
 Lymph node - ① metastatic, multiple lead 2,  
 ② lymph node, lead 2, 3, pancreatic C.  
 Cytology (RA) ①  
 No added nodes  
 RA - . scapular mass, size - 1.5 - 1.5 cm  
 . spleen - not palpable  
 CNS - ① encephalopathy  
 ② LHM focal patchy  
 D = ? Metastatic Neuroblastoma.

Admission T/C/E/C/T exam

- 1) USG abdomen - 2 dates for tumor biopsy
- 2) Review of available CT, use done at RA
- 3) BM biopsy, aspiration - Day case (Mig)
- 5) PET CT



- 4) Mass biopsy - NMYC to be sent
- 7) Sybil PCM (250mg/15ml) - 3ml PO stat

① Abundazole (400mg) - 1 tab PO ON stat  
 ↓ His after 14 days  
 Treat Abundazole (400mg) - 1 tab PO stat

8/9/2024 (2nd)

- 1) CBC, U-T, Ur T, Iron profile, Vit B12, Folate, INR
- 10) To review on 30/09/2024 @ RA Dept. at 2PM  
 po = clinic

DR. ADI...  
 30/09/2024



अ० भा० आ० सं० अस्पताल / A.I.I.M.S. HOSPITAL  
बहिरंग रोगी विभाग / Out Patient Department



रोगी विभाग  
UHID 107830583  
ABHA  
7870888000@aiims  
Dcpt No. 2024/030027301  
विवरण / D  
ARYAN RAJ

कक्षा / Room  
C-210  
Queue / संख्या  
N16  
Unit-III Paediatric

OPR-6

S/O HARENDRA KUMAR  
57 JALID / ANUPAM  
GOGARI JAWALPUR KHAGERA BHAR  
Pin D INDIA  
Ph: 7870888000  
New Patient

वय / Age

निर्दिष्ट नं./OPD Regn No

107830583  
paedi



निदान/Diagnosis

① Suprarenal mass & metastasis ( ? Metastatic ? Metastatic )

② Neuroblastoma & Metastasis

दिनांक/Date

BP - 12/11/20

*वेर*

*20*

DOB - 18.12.2019

wt - 10.5kg (-2.99)

ht - 99cm (-2.10)

w/h - -4.50

वर्किंग - *फ्लैक*

Electrolyte Inv

Ca - 11

LTU - 696

B12 - 193

PBS - Basophilic

in

S.Tw - 39

Transfer - 19.35

VMA - 242 - 0.74

VMA - 242 - 0.74

उपचार/Treatment

*10/5*  
Chief Complaint.

1) Fever - on & off

2) Pallor - 6 months

3) Multiple metastasis, one scalp & neck - 2 months

4) Proptosis of @ eye → @ eye - 2 months

5) H/O of wt loss

BT → April, just 2 times in 1st instance.

6) Pain abdomen - 1 month.

7) H/O of wt loss

8) Anemia - requiring BT - 2 times

9) Proptosis of @ eye → @ eye

10) H/O of wt loss

11) H/O of pain abdomen - epigastric, not radiate.

12) H/O of pain in both leg, back.

13) H/O of abnormal body

14) H/O of abnormal body

15) H/O of abnormal body

16) H/O of abnormal body

17) H/O of abnormal body

18) H/O of abnormal body

19) H/O of abnormal body

20) H/O of abnormal body

21) H/O of abnormal body

22) H/O of abnormal body

23) H/O of abnormal body

24) H/O of abnormal body

25) H/O of abnormal body

CLEAN AND GREEN AIIMS / एम का रोगी सक्षम स्वच्छता में जगता बना

अंगदान जीवन का बहुमूल्य उपहार / ORGAN DONATION - A GIFT OF LIFE

45714 O.R.B.O., AIIMS, 26588360, 26593444, www.orbo.org Helpline - 1050 (24 hrs service)





भारत सरकार

GOVERNMENT OF INDIA



हरराम कुमार

Hararam Kumar

जन्म तिथि / DOB: 06/05/1995

लिंग / GENDER: MALE



3808 0977 0116

आधार - आम आदमी का अधिकार



भारतीय विशिष्ट पहचान प्राधिकरण  
INDIAN IDENTIFICATION AUTHORITY OF INDIA

पता:

Address:

आत्मज: महेश्वर मंडल, वॉर्ड  
न 04, मलीया, पोस्ट- बरि  
मलीया, मोलिया, खगड़िया,  
बिहार - 851203

SO: Maheshwar Mandai, ward  
no 04, malia, post- Bari malia,  
Molia, Khagaria,  
Bihar - 851203

3808 0977 0116

**Aadhaar**-Aam Admi ka Adhikar



भारत सरकार  
GOVERNMENT OF INDIA



आर्यन राज  
Aryan Raj  
जन्म तिथि/DOB: 2019  
पुरुष/ MALE

**7822 0609 6424**

VID : 9101 7354 1743 4896

मेरा आधार , मेरी पहचान