

Department of Pediatrics  
Division of Pediatric Oncology  
All India Institute of Medical Sciences, New Delhi

CK = No - 62245



शरीरमाद्यं खलु धर्मसाधनम्

**Patient Note Book**

Name : ..... Rishab .....

UHID : ..... 105911029 .....

Diagnosis : ..... B - ALL .....



UHID: 105911029 Reg Date: 09/04/2022 01:45 PM  
Patient Name: Master. RISHAB .  
Sex: Male Age: 6 years 25 days  
Department: Paediatrics Unit Name: Unit-III  
Unit Incharge: Dr. S. K. KABRA Sample Collection Date: 04/05/2022 09:37 AM  
Lab Name: Oncology Lab Lab Sub Centre: Lab Oncology (IRCH)  
Sample Received Date: 04/05/2022 02:42 PM Report Generated Date: 05/05/2022 11:42 AM  
Dept / IRCH No: 20220030005677 Recommended By: Dr. Nisha PEDS  
Lab Reference No: 1673  
Ward Name: C5 DAY CARE

**Sample Details : LOI-040522036-PS (Blood)**

**PS**

**WBC :**

N 67 L 27 E M 5 B Meta Myelo Pro  
Blast 1 Others

**Cell Morphology**

RBC: Ncyt + Nchrom + Aniso + Micro + Macro Polk Elipto Dachro  
Schisto Acantho  
Crenat Sphero Blister Bite Hypo + Target Polychr  
Anisochrom Nucleated RBC  
HJ Body Baso Stipl Cabot ring Parasite Rouleaux Agglutination Others

**PLATELETS:** adequate.

**Notes:**

Senior Resident: Dr Mita Patel  
Consultant: Dr Ritu Gupta

Authorized Signatory



प्रयोगशाला अबुर्द विज्ञान, डॉ. भीमराव अम्बेडकर संस्थान रोटरी कैंसर अस्पताल  
अखिल भारतीय आयुर्विज्ञान संस्थान नयी दिल्ली -110029  
LABORATORY ONCOLOGY, Dr B.R.A. Institute Rotary Cancer Hospital All India Institute  
of Medical Sciences, New Delhi-110029

UHID:	105911029	Reg Date :	09/04/2022 01:45 PM
Patient Name :	Master. RISHAB .	Age :	6 years 13 days
Sex :	Male	Unit Name :	Unit-III
Department :	Paediatrics	Sample Collection Date:	22/04/2022 12:16 PM
Unit Incharge :	Dr. S. K. KABRA	Lab Sub Centre:	Lab Oncology (IRCH)
Lab Name:	Oncology Lab	Report Generated Date:	27/04/2022 10:19 AM
Sample Received Date:	23/04/2022 12:07 PM	Recommended By:	Dr. Dilip SR Paeds
Dept / IRCH No:	20220030005577		
Lab Reference No:	1273		
Ward Name:	C5 DAY CARE		

Sample Details : LOI-220422079-FM (Bone Marrow)

**FLOWCYTOMETRY (BONE MARROW)**

F-1273/22

Bone marrow aspirate sample sent for flow cytometric analysis is markedly hemodiluted. However, shows approx. 15% CD45 dim+ blasts which are CD19+, CD10+, cCD79a+, CD58+, CD123+, CD38 heterogeneous+, CD81+ and are negative for cMPO, CD34, CD33, CD13, CD7, cCD3, sCD3, CD117, CD304, CD73, CD20 and CD56.

**Impression:- Blasts are of B lymphoid lineage**

**Advice:- Clinical correlation**

**Senior resident:- Dr. Ekta Rahul**

**Consultant In-charge:- Dr. Nupur Das**

**Authorized Signatory**





प्रयोगशाला अबुर्द विज्ञान, डॉ भीमराव अम्बेडकर संस्थान रोटरी कैंसर अस्पताल  
अखिल भारतीय आयुर्विज्ञान संस्थान नयी दिल्ली -110029  
LABORATORY ONCOLOGY, Dr B.R.A. Institute Rotary Cancer Hospital All India Institute  
of Medical Sciences, New Delhi-110029

UHID:	105911029	Reg Date :	09/04/2022 01:45 PM
Patient Name :	Master. RISHAB .	Age :	6 years 13 days
Sex :	Male	Unit Name :	Unit-III
Department :	Paediatrics	Sample Collection Date:	22/04/2022 09:53 AM
Unit Incharge :	Dr. S. K. KABRA	Lab Sub Centre:	Lab Oncology (IRCH)
Lab Name:	Oncology Lab	Report Generated Date:	27/04/2022 11:07 AM
Sample Received Date:	23/04/2022 11:19 AM	Recommended By:	Dr. Dilip SR Paeds
Dept / IRCH No:	20220030005877		
Lab Reference No:	1218		
Ward Name:	C5 DAY CARE		

Sample Details : LOI-220422033-AP (Bone Marrow)

**BMA PS**

Report: Bone marrow aspirate is largely hemodiluted and shows ~ 25% blasts in available cellularity. Blasts are negative for MPO.

Peripheral blood smear shows ~ 20% blasts and thrombocytopenia.

Imp : Acute leukemia

Advice: 1) Immunophenotyping

2) Molecular and cytogenetic studies

Senior Resident: Dr Mita Patel

Consultant: Dr Nupur Das

Authorized Signatory



# Karē Diagnostic

Facilities : ● Colour Doppler ● 3D/4D Ultrasound

PATIENT NAME	MR. RISHAB	AGE/ SEX	05 Y/M
RAF.BY	SELF	DATE	06 /04/2022

## ULTRA SOUND WHOLE ABDOMEN

**LIVER** — is normal in size & shape. **It shows increased echo texture.** Intra hepatic biliary radicals Appear normal. There is no evidence of space occupying lesion.

**GALL BLADDER** — is normal in size & shape with anechoic lumen. No calculus is seen. No wall thickening is seen.

**C.B.D** — Normal in caliber. No calculus or growth seen.

**PORTAL VEIN** — is normally visualized with normal caliber.

**PANCREAS** — is normal size & in echo texture. No mass or calcification is seen. Pancreatic duct is not dilated.

**SPLEEN** — **is massive enlarged in size 133 mm.**

**RIGHT KIDNEY** — is normal in size, shape & echo pattern. Cortico-medullary distinction is maintained. No Evidence of calculus or hydronephrosis seen.

**LEFT KIDNEY** — is normal in size, shape & echo pattern. Cortico-medullary distinction is maintained. No Evidence of calculus or hydronephrosis seen.

**URINARY BLADDER** — is normally visualized. No evidence of calculus or mass is seen. No wall is thickened.

**OTHER** - **BOWEL LOOPS ARE DILATED WITH GASSES SEEN IN INTESTINE**

**IMPRESSION** ===== **1. MASSIVE SPLENOMEGALY 2. BOWELS/ GASSES**

**ADV. ===== CBC ,ENDOSCOPY & PLEASE CORRELATE CLINICALLY.**

=====END OF THE REPORTS=====

This is a professional opinion and not a diagnosis; ALL MODERN MACHINES/ PROCEDURES HAVE THEIR LIMITATIONS. IF THERE IS VARIANCE CLINICALLY THIS EXAMINATION MAY BE REPEATED OR RE-EVALUATED. OTHER INVESTIGATIONS. THIS REPORT IS NOT VALID FOR MEDICO-LEGAL PURPOSES.

DR. ABHISHEK SE  
[ M.B.B.S., SONOLU ]

📍 Lakshmi Arcade, K.P. Road, Bulandshahr- 203001 📞 8923255990, 7

All Ultra Sonographic Findings are to be Clinically correlated to other investigations for final Diagnosis. All Anomalies may not be Visible on U.S.G. Technical errors are unavailable. Advice further repeat investigation & Clinical Correlation in suspected Cases.

**Not for Medico Legal Purpose**



प्रयोगशाला अद्वैत विज्ञान, डॉ भीमराव अम्बेडकर संस्थान रोटरी कैंसर अस्पताल  
अखिल भारतीय आयुर्विज्ञान संस्थान नयी दिल्ली -110029  
LABORATORY ONCOLOGY , Dr B.R.A. Institute Rotary Cancer Hospital All India Institute  
of Medical Sciences , New Delhi-110029

UHID:	105911029	Reg Date :	09/04/2022 01:45 PM
Patient Name :	Master. RISHAB .		
Sex :	Male	Age :	6 years 1 month 4 days
Department :	Paediatrics	Unit Name :	Unit-III
Unit Incharge :	Dr. S. K. KABRA	Sample Collection Date:	13/05/2022 09:06 AM
Lab Name:	Oncology Lab	Lab Sub Centre:	Lab Oncology (IRCH)
Sample Received Date:	13/05/2022 02:30 PM	Report Generated Date:	14/05/2022 11:03 AM
Dept / IRCH No	20220030005877	Recommended By:	Dr. Nisha PEDS
Lab Reference No.	706		
Ward Name	C5 DAY CARE		

**Sample Details : LOI-130522046-CS (CSF)**

**CSF For Morphology**

C-706/22

CSF cytopsin smear is acellular

Senior Resident: Dr Mita Patel

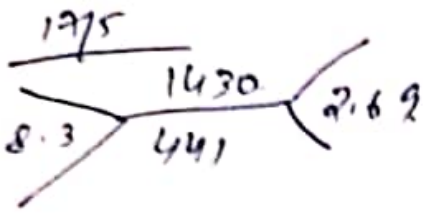
Signature: Dr Ritu Gupta

Authorized Signatory

18/5/22

B- ALL (SR) on induction

NO FC



7/5  
PP20/4 P/Key

at 0/10/11  
Clear

9/1  
cos  
cos

Adw

- T.D. kangole (15my) / Hat  
SD 88f x 100

Due for 2y' leukemia & VCR

To arrange

3 Day care team

18/5/22  
2y' leukemia Food to deep sym.

- 2y' VCR long slow to pub

- CP T. leptan / betadine gargle  
on 1st pm / 2/3 bath

- N/v P.O.P.D 22/5/22

f/c Arlecular  
cytogenetic's report

Key





आपातकालीन नं. (Emergency No): 2022/030/0026668

दिनांक DATE: 11/04/2022

समय TIME: 01:18:15 PM

NON-MLC

नाम NAME: MASTER, RISHAB .

आयु AGE : 6 years 2 days

लिंग/SEX : M

S/O : GAURAV SINGH

पता ADDRESS: मकान संख्या H.NO. VILL+POST JADOUIL गली / मुहल्ला STREET/MOH: DISTT BULANDSHAR  
 शहर/प्रखण्ड CITY/BLOCK: पिन PIN: 245409  
 राज्य STATE: UTTAR PRADESH दूरभाष सं. PHONE NO:  
 मोबाइल MOBILE NO. 9536715008 स्थान Location: Paediatrics Emergency

द्वारा BROUGHT BY: Relative : FATHER

Criticality: Red / Yellow / Green

Triage: Responsive/ Unresponsive HR /min BP mmHg RR /min SpO2 %

Shifted to Paeds/ Main/ New Emergency k/c/o Acute Leukemia (Neutropenia).

Presenting Complaints

% fever x 3 days [On/off].

Rash x 3 days. (Vesicle over dorsum hand, chest).

No/c/o abdominal pain/ loose stool / cough/ rhinorrhoea/ seizure/ ecchymosis

Primary Assessment (ABCDE) : Assessment Pentagon

<p><b>Airway</b></p> <p>Open &amp; stable : Yes/No If No.....</p> <p>Breathing: RR 28/min (Stable) Efforts: Normal/Poor/increased Auscultation: Air entry: Normal/poor/Differential</p> <p>Added sounds: None/Stridor/Wheeze/Crackles</p> <p>SpO2 on Room air 98%</p>	<p><b>Circulation</b></p> <p>HR 138/min CFT 22 secs. BP 98/60 mmHg</p> <p>Peripheral pulse: Poor/Good Central pulse: Poor/Good</p> <p>Skin temp: Warm/cool</p> <p>Others</p>	<p><b>Disability</b></p> <p>GCS 15/15</p> <p>Pupil size...../min Pupillary Reactions...PIL</p> <p><b>Motor activity:</b> Normal &amp; Symmetrical/Asymetri Posturing/Flacidity/Seizure</p> <p>Blood Sugar.....mg/dl Exposure: Temp...Warm Colour: Normal/pallor/cyanosis /mottled Any other skin lesions.....</p>
---	--	---

Wt → 13 kg → o/e → oedema over bone marrow aspirate  
 Imprecise Acute leukemia. / APL / Vantella

Diagnosis

mmHg  
CBC  
VBS  
Blow & RS.  
LFT, RFT, LDH.  
Blow (best tray)

A&V  
 1) 8hj. Zosyn 1.7g IV q8h  
 2) 8hj. Amikacin 260mg IV q24h  
 3) 8hj. Acyclovir 400mg IV q8h.  
 2-3gm 3pm 8hj. By Rem 170mg IV stat  
 3) 8hj. Teicoplanin 170mg q12h doses followed by q2

13/4/22

for/0  
Vsh - ~~the~~ collections

no obvious intra-abdominal collections seen

Dant

of Radiologist / Date :



अ० भा० आ० सं० अस्पताल / A.I.I.M.S. HOSPITAL  
बहिरंग रोगी विभाग / Out Patient Department

अस्पताल के अन्दर धूम्रपान मना है। / SMOKING IS PROHIBITED IN HOSPITAL PREMISES



एकक/Unit \_\_\_\_\_  
विभाग/Dept. \_\_\_\_\_  
नाम/Name \_\_\_\_\_

OPR-6

Regn. No. \_\_\_\_\_

पता/Address \_\_\_\_\_

Dep. No. \_\_\_\_\_

Regd. No. \_\_\_\_\_

Age \_\_\_\_\_ Sex \_\_\_\_\_

HT \_\_\_\_\_ WT \_\_\_\_\_

S/O LABRA DWA

PH. 313671000

UNIQ : 100611079 Date: 07/05/2022

निदान/Diagnosis

दिनांक/Date

28

15-8 kg.

उपचार/Treatment

Nastr  
18/5/22

N/O - P.O.P.P. - 1/6/22

[Signature]

शरीरमाद्यं खलु धर्मसाधनम्



CLEAN AND GREEN AIIMS / एम्स का यही संकल्प, स्वच्छता से काया कल्प  
अंगदान-जीवन का बहुमूल्य उपहार / ORGAN DONATION - A GIFT OF LIFE  
O.R.B.O., AIIMS, 26588360, 26593444, www.orbo.org Helpline - 1060 (24 hrs service)



1

Found  
1 / 5074

122-0607



**Laboratory Oncology Unit**  
Dr. B.R.A. IRCH, All India Institute of Medical  
Sciences  
Ansari Nagar, New Delhi-110029

UHID Reg. No	105911029	Molecular Lab ID	T22-0607
Name	RISHAB	IRCH No.	
Sex	Male	Sample Type	Bone Marrow Aspirate
Age	6Y	Sample Volume	2ML
Department	PAEDIATRICS	Diagnosis	B-ALL
Unit	III	Sample Receipt Date	22/04/2022
Consultant Name	Dr. Rachna Seth	Report Date	05/05/2022

**RT PCR DETECTION OF:**

BCR-ABL t(9;22)

PML-RARA t(15;17)

AML-ETO t(8;21)

CBFB-MYH11 t(16;16)/inv(16)

MLL-AF4 t(4;11)

E2A-PBX1 t(1;19)

TEL-AML1 t(12;21)

SIL-TAL1

**PCR DETECTION OF:**

FLT3-TKD (D835Y) MUTATION

MYD88 (L265P) MUTATION

JAK2V617F MUTATION

**S OF:**

MUTATION

NPM1 ALLELIC RATIO

FLT3-ITD MUTATION

FLT3-ITD ALLELIC RATIO

**Comments & Interpretation**

BCR-ABL, MLL-AF4, E2A-PBX and TEL-AML fusion transcripts were not detected by RT-PCR.

Test Done By

Checked by:

Reviewed & Authorized by: Consultant  
Dr. Ritu Gupta

Pediatric  
CL No 20/2003/5416877  
UHID 105911029  
RISHAB . 8Y28W  


Pediatric  
Queue No: F30  
Room 14  
UHID 105911029 18-05-2022  


5

15.Kg



भारत सरकार

Government of India




गौरव सिंह

Gaurav Singh

जन्म तिथि / DOB : 10/07/1991

पुरुष / Male



5766 0471 2761

मेरा आधार, मेरी पहचान



भारतीय विशिष्ट पहचान प्राधिकरण

Unique Identification Authority of India

पता: आत्मज: प्रेमवीर सिंह, जाडौल,  
जडौल, बुलंदशहर, जडौल, उत्तर  
प्रदेश, 245409

Address: S/O: Premvir Singh, Jadaul,  
Jadaul, Bulandshahr, Jadaul, Uttar  
Pradesh, 245409

**5766 0471 2761**



1947



help@uidai.gov.in

WWW

www.uidai.gov.in